http://journal.unoeste.br/index.php/cv
DOI: 10.5747/cv.2022.v14.n.v353
ISSN on-line 1984-6436

Colloquium Vitae

Submetido: 17/03/2022 Revisado: 08/09/2022 Aceito: 24/09/2022

SEVERE NEUROLOGICAL MANIFESTATIONS OF COVID-19: CASE SERIES

Anna Carolina de Almeida Sufen, Helton Otsuka, Estefânia Costa Ribeiro, Maria Teresa Fernandes Castilho Garcia

[1]Universidade do Oeste Paulista – UNOESTE, Presidente Prudente, SP. E-mail:

ABSTRACT
SARS-CoV-2 is the etiologic agent of the pandemic started in December 2019 and has been reaching alarming numbers worldwide. Neurological manifestations have been reported and must be highlighted. This study reports cases of severe neurological manifestations associated with COVID-19 in patients admitted to a tertiary hospital. The first patient was referred with history of generalized seizures after the diagnosis of COVID-19; imaging exam indicated cerebral venous thrombosis. The second patient, already treated for COVID-19, developed pain in the dorsal region, progressing to ascending paresthesia, and had diagnosis of Guillain-Barré Syndrome, with fatal outcome. The third patient, also with fatal outcome, presented with headache and left hemiparesis. After imaging exams, was discharged, but days after, returned with mental confusion and the hypothesis of encephalitis was confirmed. SARS-CoV-2 infection was confirmed after death. The main objective of this study is to report severe neurological manifestations related to COVID-19.
Keywords: COVID-19, neurologic manifestations, venous thrombosis, guillain-barre syndrome, encephalitis.

MANIFESTAÇÕES NEUROLÓGICAS GRAVES DA COVID-19: SÉRIE DE CASOS

RESUMO
O SARS-CoV-2 é o agente etiológico da pandemia iniciada em dezembro de 2019 e vem atingindo números alarmantes em todo o mundo. Manifestações neurológicas foram relatadas e devem ser destacadas. Este trabalho relata casos de manifestações neurológicas graves associadas à COVID-19 em pacientes internados em um hospital terciário. O primeiro paciente foi encaminhado com história de convulsões generalizadas após o diagnóstico de COVID-19; exame de imagem indicou trombose venosa cerebral. O segundo paciente, já tratado para COVID-19, desenvolveu dor na região dorsal, evoluindo para parestesia ascendente, e teve diagnóstico de Síndrome de Guillain-Barré, com desfecho fatal. O terceiro paciente, também com desfecho fatal, apresentou cefaléia e hemiparesia à esquerda. Após exames de imagem, recebeu alta, mas dias depois, retornou com quadro de confusão mental e foi confirmada a hipótese de encefalite. A infecção por SARS-CoV-2 foi confirmada após a morte. O principal objetivo deste estudo é relatar manifestações neurológicas graves relacionadas à COVID-19.
Palavras-chave: COVID-19, manifestações neurológicas, trombose venosa, síndrome de Guillain-Barré, encefalite.

INTRODUCTION

The increasing number of cases of the pandemic caused by the new coronavirus, named SARS-CoV-2 (Severe Acute Respiratory Syndrome Coronavirus 2), the etiological agent of the disease COVID-19 (Coronavirus Disease 2019), is alarming, approaching 390 million confirmed cases and with more than 5.7 million deaths as of February 4, 2022[1,2].

The main mode of transmission of SARS-CoV-2 is person-to-person, which can be through close or direct contact[3,4]. Transmission is most

Artigo Open Access sob uma licença CC BY-NC-ND (http://creativecommons.org/licenses/by-nc-nd/4.0/).

frequent by microdroplets produced during coughing, sneezing and speaking[4]. The clinical course of COVID-19 is broad and ranges from asymptomatic infection to death; however, its most frequent signs and symptoms are similar to those of flu and other coronaviruses, such as fever, cough and asthenia[5,6]. An increasing number of studies have described extrapulmonary manifestations, suggesting that hematologic, cardiovascular, renal, gastrointestinal, hepatobiliary, endocrine, ophthalmologic, dermatologic, and neurologic systems may be affected[1,7]. Neurological manifestations range from mild to severe and a recent study has shown that SARS-CoV-2 can infect neurons and this non-respiratory infection is associated with mortality[8,9].

Moderate neurological symptoms such as anosmia or hyposmia, ageusia or hypogeusia, anorexia, visual dysfunction, and neuralgia were reported, with taste and smell disfunction reported by 88% and 85%, respectively, in a study of 417 mild or moderate COVID-19 patients[1,5,8,10]. Severe neurological manifestations, although rare, are also being reported and include several categories of cerebrovascular events (ischemic stroke, intracerebral haemorrhage, and cerebral venous thrombosis), epilepsy, acute necrotizing encephalopathy, meningitis, encephalitis, encephalopathy and Guillain-Barré Syndrome (GBS)[1,5,8,10].

Neurological manifestations may present simultaneously, or even before the initial respiratory symptoms, and this has been referred to as NeuroCOVID[11]. As explained above, the neurological manifestations resulting from SARS-CoV-2 infection, especially the severe ones, should be investigated and this paper aims to contribute to searching information that will help physicians to understand this new disease and, thus, to avoid further deaths.

This series was approved by the Research Ethics Committee of Universidade do Oeste Paulista (CAAE nº 47826921.5.0000.5515).

CASE DESCRIPTION 1

A 29-year-old female patient with headache and hypogeusia presented with 3 generalized tonic-clonic seizures (GCTS), being admitted to the hospital. A real time polymerase chain reaction (RT-PCR) was performed, confirming infection by SARS-CoV-2. She underwent a computed tomography scan (CT scan) of the head and an examination of the cerebrospinal fluid (CSF), with no changes being found. After three days of hospitalization, she was discharged, starting treatment with hydroxychloroquine and an antiseizure medication.

As the patient did not have personal or family history of neurological diseases, an investigation to clarify the aetiology of GCTS has started. Electroencephalography (EEG) and brain magnetic resonance imaging (MRI) were performed 6 days after discharge, the first being within the normal range and the second being altered, with hypersignal on T1 affecting the right superior anastomotic vein and on the left transverse sinus with intraluminal filling failures in the post-contrast phase (figures 1 and 2), consistent with cerebral venous thrombosis (CVT). Head MRI also identified subarachnoid haemorrhage in the bilateral frontoparietal region and cytotoxic oedema in the left perirolandic region.

Artigo Open Access sob uma licença CC BY-NC-ND (http://creativecommons.org/licenses/by-nc-nd/4.0/).

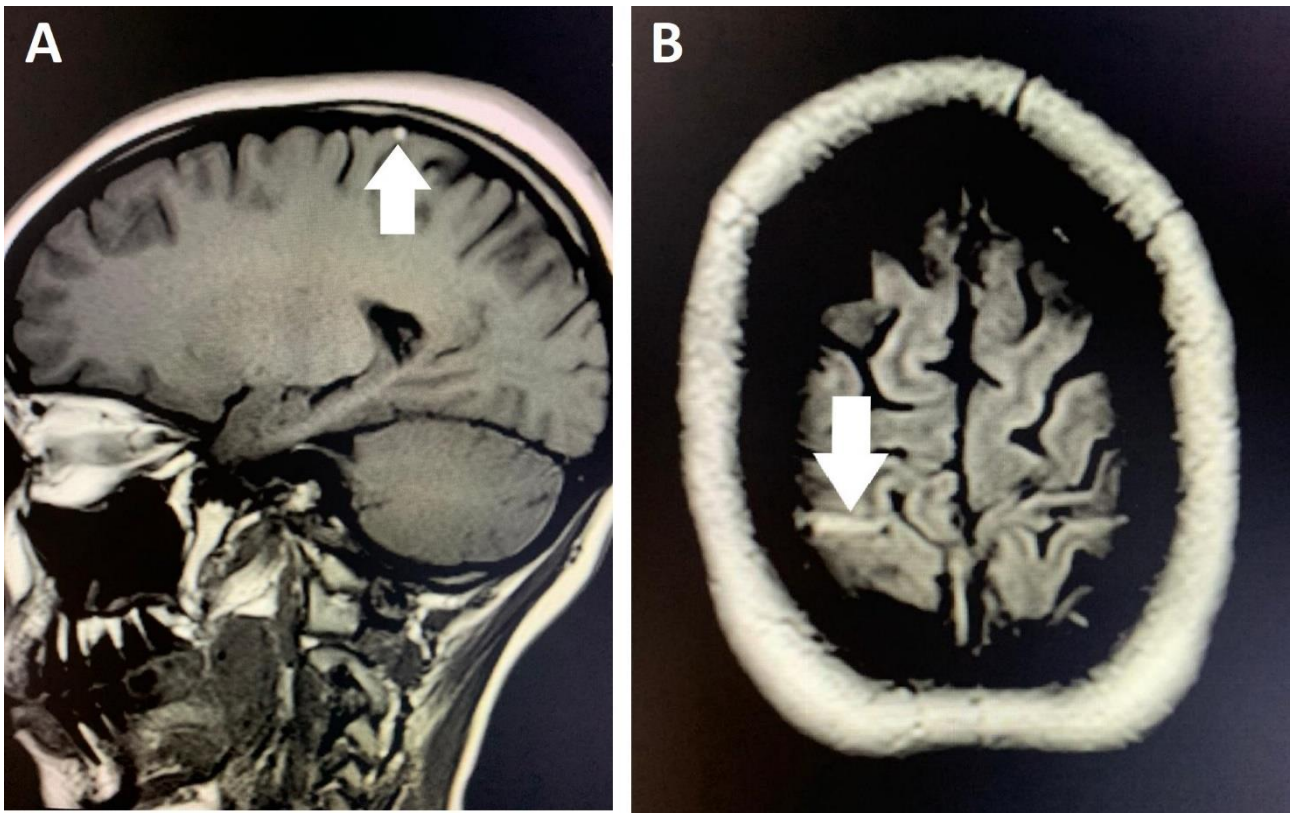

Figure 1. Thrombus on the right superior anastomotic vein, sagittal (A) and axial (B) views, indicated by the arrows.

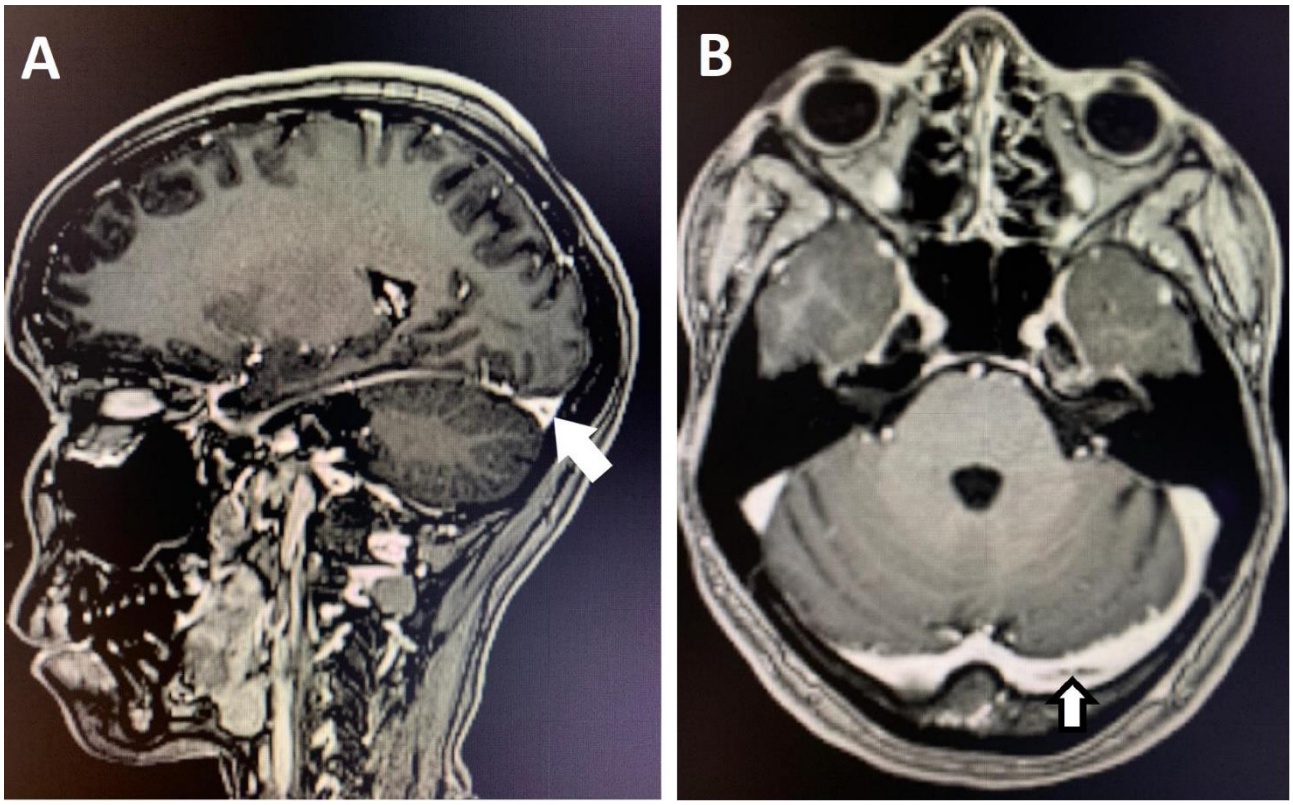

Figure 2. Left transverse sinus filling failure, sagittal (A) and axial (B) views, indicated by arrows.

The patient was referred to a tertiary hospital, reporting headache and blurred vision, initiating anticoagulation treatment. Treatment was initiated with enoxaparin and warfarin, and patient was discharged without complications, with the prescription of warfarin and orientation for weekly monitoring of the international normalized ratio (INR).

Artigo Open Access sob uma licença CC BY-NC-ND (http://creativecommons.org/licenses/by-nc-nd/4.0/).

Patient was readmitted to the hospital ten days after discharge due to elevation in INR levels (5.48); the use of warfarin was suspended and treatment with rivaroxaban was initiated. Another MRI was performed and patient was discharged with rivaroxaban, fully recovering without neurological sequelae.

CASE DESCRIPTION 2

54 years old female patient, with confirmed diagnosis of COVID-19 and symptoms of dyspnea and chest pain, presented, approximately one week after diagnosis, with severe pain in the dorsal region, associated with ascending paresthesia of the lower limbs, evolving with paresthesia of the upper limbs. Patient developed acute respiratory failure and was submitted to orotracheal intubation (OTI) and mechanical ventilation (MV). At admission, patient presented with hemodynamic stability and vesical catheterization due to urinary retention.

Chest CT on admission demonstrated ground-glass opacities with involvement of multiple lung lobes. Non-contrast head CT showed no abnormalities.

Neurological examination demonstrated flaccid tetraparesis with lower limbs areflexia, hyporeflexia in left upper limb and normoreflexia in right upper limb, grade 0 strength in lower limbs, grade 4 in left upper limb and grade 2 in right upper limb.

Patient was transferred to the intensive care unit (ICU) with the hypothesis of GBS, and as a differential diagnosis, transverse myelitis, and was submitted to lumbar puncture on two occasions, not possible to collect CSF, suggesting the hypothesis of spinal block. From the third to the fourth day of hospitalization, the patient developed hemodynamic instability, requiring the use of vasoactive drugs. Due to hemodynamic instability, head and spine MRI were not performed.

At the beginning of the fifth day of hospitalization, patient evolved with fever and worsening of hemodynamic instability not responsive to vasoactive infusion, evolving to cardiopulmonary arrest in pulseless electrical activity, with no response to resuscitation maneuvers, progressing to death.

CASE DESCRIPTION 3

40-year-old female patient admitted to the hospital due to a severe headache associated with sudden left hemiparesis. The patient presented facial paralysis 1 month before hospital admission. Head CT and MRI, arteriography and CSF examination were performed.

CT and MRI of the head showed a subacute temporal ischemic area on the right and a saccular aneurysm in the left internal carotid artery. The exams were complemented with arteriography, confirming two saccular aneurysmal formations in the left internal carotid artery. The hypothesis of ruptured aneurysm was not confirmed after a normal CSF. After eight days of hospitalization, the patient was discharged and referred for endovascular treatment.

Three days after discharge, patient developed mental confusion and was readmitted to the hospital. At the moment of admission, patient presented tachycardic, but with no hemodynamical instability, and neurological examination showed mental confusion and temporo-spatial disorientation. Due to an acute confusional syndrome, a head CT was performed, which showed no new acute changes.

On the second day of hospitalization, the patient presented with a rapid decrease in the level of consciousness, with non-photoreactive mydriatic pupils, requiring OTI and MV. After OTI, she evolved with persistent hypertensive levels.

The hypothesis of encephalitis was suggested, and CSF results were erythrocytes 160/mm^3, leukocytes 300/mm^3, with 96% lymphocytes and 4% neutrophils, glucose 78 mg/dL, proteins 186 mg/dL and no *Cryptococcus* sp. Empirical treatment was started for herpetic and bacterial encephalitis and tests for SARS-CoV-2, infectious serology and EEG were requested.

EEG exhibited moderately disorganized and symmetrical background activity and very frequent presence of generalized periodic discharges (GPDs), a pattern that can be found in encephalitis of different aetiologies.

On the third day of hospitalization, patient developed fever followed by bradycardia, high levels of blood pressure and non-reactive pupils.

On the seventh day of hospitalization, patient presented clinical worsening and no brain stem reflexes, associated with hemodynamic instability, progressing to death. On this day, SARS-CoV-2 infection was confirmed by RT-PCR exam.

Artigo Open Access sob uma licença CC BY-NC-ND (http://creativecommons.org/licenses/by-nc-nd/4.0/).

DISCUSSION

Neurological symptoms are common in COVID-19, however it is not known how SARS-CoV-2 infection leads to neurological manifestations, and the pathophysiological mechanism to reach the central nervous system (CNS) is not clear[12]. The two main hypotheses under discussion are based on neurotropism, with direct damage to the CNS, or on indirect mechanisms[12].

SARS-CoV-2 is capable of penetrating target cells through the binding of its Spike protein with the angiotensin-converting enzyme 2 (ACE2) receptor, present in several cells, such as neurons and glial cells[1,5,10]. The proposed pathophysiological mechanisms of neuroinvasion include direct invasion with dissemination through the cribriform plate of the ethmoid bone, the neuronal pathway through the olfactory bulb, and the hematogenous pathway with damage to the blood-brain barrier through attack on the vascular system[5]. In addition, neurological manifestations may result from indirect effects on the CNS, related to hypoxia resulting from disturbances of alveolar gas exchange, hypertension resulting from the binding of viral particles to ACE2, coagulopathies and neurological damage caused by an immune response[5].

Matschke et al. performed a series of brain autopsies and concluded that neuropathological brain changes were relatively mild, although concluding that SARS-CoV-2 is able to reach CNS[12]. Furthermore, this study concluded that it is more likely that such changes are related to the immune response and that there is no direct evidence that SARS-CoV-2 can cause damage to the CNS[12].

Although the neuropathology of COVID-19 is not yet fully understood, the literature is abundant in relation to the neurological manifestations resulting from SARS-CoV-2 infection and our study contributes to this regard.

In this study, we report three cases of severe neurological manifestations related to COVID-19, with the first case presenting a cerebrovascular complication, diagnosed with CVT; in the second case, it was not possible to confirm the diagnosis of transverse myelitis and GBS as differentials, due to the rapid hemodynamic instability and evolution to death; and the third case presented with encephalitis.

The diagnoses presented in our study appear in several studies found in literature. Approximately 5 months after the identification of SARS-CoV-2, Ellul et al. published a quick literature review, in which they found case reports with total of 901 patients with neurological manifestations, of which 93 had encephalopathy, 8 encephalitis, 19 GBS and 96 had cerebrovascular events[7].

To investigate the complications of COVID-19 affecting the brain in the UK, an online case-sharing network involving leading UK neuroscience bodies was created, and 153 cases were reported, of which 62% were related to cerebrovascular events, 31% altered mental status (23% with nonspecific encephalopathies and 18% with encephalitis) and 5% had peripheral disorders (in which 67% were diagnosed with GBS)[13].

In a study conducted in France, 222 patients diagnosed with COVID-19 who presented neurological manifestations were included[14]. Among these, 30.2% had encephalopathy, 25.7% had cerebrovascular syndrome, 9.5% had encephalitis, and 6.8% had GBS[14].

A recent review found five cohort studies totalling 2533 patients with neurological manifestations resulting from COVID-19[15]. Another four cohort studies were found with a specific focus on neurological manifestations of COVID-19, describing 482 patients, and 57 publications reporting 98 cases of patients with neurological diseases related to COVID-19[15]. The results were: CNS manifestations, mainly nonspecific encephalopathies that represented between 13% and 40% of all neurological manifestations; post-infectious syndromes including acute demyelinating encephalomyelitis (ADEM) (n=13), acute necrotizing encephalopathy (n=4), Bickerstaff encephalitis (n=5), generalized myoclonus (n=3) and acute transverse myelitis (n=7); other encephalitis, including limbic encephalitis (n = 9) and miscellaneous encephalitis with variable radiological findings (n = 26); acute cerebrovascular diseases, including ischemic stroke (between 1.3% and 4.7% of patients with COVID-19), haemorrhagic stroke (n=17), CVT (n=8), and posterior reversible encephalopathy (PRES) (n=5)[15]. The peripheral nervous system (PNS) manifestations reported in COVID-19 were the following: GBS (n = 31) and variants, including Miller Fisher syndrome (n = 3), cranial neuropathies (n = 2) and facial diplegia (n = 2); isolated oculomotor neuropathy (n = 6); critically ill patient myopathy (n = 6)[15].

Artigo Open Access sob uma licença CC BY-NC-ND (http://creativecommons.org/licenses/by-nc-nd/4.0/).

CVT represents only 0.5-1% of all strokes and it presents with a variety of neurological signs and symptoms, occurring predominantly in younger patients and women[16]. Viral infections are rarely a direct cause of CVT, but increased risk of stroke is reported in cases of COVID-19, including CVT, due to the hypercoagulability state[16].

Recent studies report the potential for the development of a hypercoagulability state in SARS-Cov-2 infection[17]. General infections can promote endothelial cell dysfunction, leading to overproduction of thrombin and inhibition of fibrinolysis[17]. Furthermore, hypoxemia is associated with increased blood viscosity and activation of genes that mediate coagulation and fibrinolysis, favouring the occurrence of thrombotic events[17].

The coagulopathy syndrome associated with COVID-19 presents in the laboratory as increased levels of D-dimer, lactic dehydrogenase (LDH) and prolonged clotting time[18,19].

CVT has a variety of signs and symptoms and early identification is essential so that anticoagulation and/or endovascular treatment can be administered, to decrease the progression of cerebral oedema, increase in intracranial pressure and haemorrhage levels, improving the prognosis[17]. In the first case reported, the patient had 3 GCTS, and was admitted with headache and blurred vision, 11 days after the diagnosis of COVID-19; and was treated with anticoagulation.

In a systematic review by Tu et al., 91.7% of patients received treatment with anticoagulants[20]. Unfractionated heparin is cited as the best and best-known treatment for CVT[20]. They also recommend the use of anticoagulants in hospitalized patients with COVID-19, since the literature shows that those who received such treatment evolved with a better prognosis[20]. In our first reported case, the patient was treated with heparin and was discharged on oral anticoagulation with warfarin.

In the first half of 2020, lower numbers of neurological hospitalizations, and CVT cases specifically, were reported[18]. Researchers believe that this is due to the pandemic scenario itself, where there was a high probability that patients, especially with mild symptoms, did not seek medical care for fear of the possibility of contracting COVID-19; as well as the possibility that CVT cases have been underdiagnosed, due to the need for patients with COVID-19 and cardiopulmonary instability to be sedated and submitted to OTI[17]. Still, more and more cases of CVT are reported in patients with COVID-19[20]. Considering the global increase in cases, and the severity of CVT as a complication, a deeper understanding of its association, clinical manifestations, severity and treatments is needed[20].

GBS can occur in already known infections like *Campylobacter jejuni, Haemophilus influenzae, Mycoplasma pneumoniae*, Zika Virus, but it has also been reported in cases of COVID-19, during or after the course of SARS-CoV-2 infection[21].

The infection promotes a cross-reaction in peripheral nerve ganglia by mimicry of peripheral nerve neural cells, which causes nerve conduction blockage or axonal degeneration[21], stimulating an autoimmune response of T cells and lymphocytes, causing neural dysfunctions[22].

In severe manifestations, demyelination of peripheral nerves occurs, generating manifestations of paresthesia, strength deficit, bilateral ascending paralysis, and reaching the diaphragmatic nerves, generating the need for ventilatory support[23].

Among the most common manifestations of GBS are a rapid-course neuromuscular disorder, more specifically acute inflammatory demyelinating polyneuropathy, facial diplegia, paresthesia, ataxia, areflexia, which may affect upper and lower limbs, and tetraparesis[24]. These diverse motor conditions may indicate an association with autoimmune diseases and idiopathic factors[25]. Some literatures report that one of the possible forms of viral infection occurs through reactive immune sensitization caused by the mimicry between virus epitopes with nerve epitopes, triggering neural lesion[26].

Transverse myelitis (TM) is a rare syndrome that affects the spinal cord, triggering an inflammatory process, causing paresthesia, dysesthesia, urinary incontinence, constipation and sexual dysfunction. TM results from complications from previous diseases, or from an idiopathic cause, bacterial infections and viral infections[17]. TM is one of the manifestations of SARS-CoV-2. Among the characteristics that the disease can present is severe respiratory difficulty, anosmia, muscle weakness, numbness and tingling, which occurs due to the inflammatory cascade affecting the myelin sheath and spinal cord, and may progress to severe deficit bilaterally on the lower limbs, progressing

Artigo Open Access sob uma licença CC BY-NC-ND (http://creativecommons.org/licenses/by-nc-nd/4.0/).

with involvement of the upper limbs and difficulty urinating and defecating[17].

Encephalopathy and encephalitis were the most frequent complications found in a recent study that included 232 cases of patients with neurological manifestations resulting from COVID-19, representing 21.9% of the total cases[27]. The third patient presented a clinical status compatible with encephalitis, with headache and focal neurological deficit as the main symptoms, since the first hospitalization, evolving with clinical worsening of mental status and fever.

In a systematic review on CSF analysis that defines neurological manifestations of COVID-19, the most common changes found were elevated total protein accompanied, very occasionally, by pleocytosis with moderate lymphocytosis[28]. In 100% of fatal cases, CSF protein was elevated, averaging 61.28 mg/Dl[28]. In our case, protein levels was three times higher than the average found in the aforementioned study.

In another study, CSF of 60 patients were analysed, also presenting the result of protein elevation and pleocytosis[29]. However, it was concluded that patients with neurological manifestations associated with COVID-19 had different CSF profiles, even within the same neurological condition[29]. In this study, patients classified in the group of inflammatory neurological diseases, which included those diagnosed with encephalitis (n = 2), had a mean protein value of 40.5 mg/dL and a mean of 16 leukocytes/mm^3, predominantly consisting of mononuclear cells (> 80%), and patients diagnosed with meningoencephalitis and meningitis had the highest values, ranging from 8 to 396 cells/mm^3, which can also be seen in our case[29].

In the study conducted by Abildúa et al. alterations were found in 23.5% of cranial CT performed and in only 15.7% of brain MRI, concluding that these radiological studies showed low specificity and sensitivity in the diagnosis of encephalopathies and encephalitis resulting from COVID-19[27]. Contrarily, in the study undertaken by Meppiel et al., of the patients diagnosed with COVID-19, 66.7% had brain MRI with alterations compatible with encephalitis[14]. Compared to the results obtained from imaging tests, EEG has been the most sensitive test in the diagnosis of encephalitis and encephalopathies, showing alterations in 93.3% of patients diagnosed with encephalitis related to COVID-19[14,27]. Two studies suggest a possible EEG pattern specific to COVID-19 patients, showing periodic monomorphic and biphasic slow delta waves in frontal areas[15]. These periodic discharges were also observed in the EEG of the patient 3.

The treatment of encephalitis cases related to COVID-19 described in the literature varies, with the main pharmacological groups chosen being high-dose corticosteroids, intravenous immunoglobulin and immunomodulators such as rituximab and tocilizumab[30,31]. Patient 3, diagnosed with encephalitis, had no time to receive specific treatment.

Mortality rates of COVID-19-related inflammatory neurological diseases found in literature also vary, ranging from 4.8% to 12%[14,15,27].

The onset of neurological manifestations varies in cases of SARS-CoV-2 infection and this study presents cases that confirm this reality. In case 2, the patient presented neurological complications after respiratory symptoms and the diagnosis of COVID-19. In cases 1 and 3, the neurological manifestations preceded the diagnosis of COVID-19 and there are no records of respiratory symptoms.

Meppiel et al. stated that neurological manifestations occurred after the first symptom of COVID-19, with a mean delay of 7 days for encephalitis, 12 days for acute ischemic cerebrovascular syndrome, and 18 days for GBS[14]. On the other hand, there are studies reporting that various neurological manifestations can occur in patients infected with SARS-CoV-2 without clinical manifestations of respiratory dysfunction[32]. In a review, it was concluded that patients with COVID-19 may develop neurological manifestations before, during, and even after the onset of common symptoms of COVID-19[4].

Another important factor is the delay between the onset of neurological complications and the confirmation of SARS-CoV-2 infection, which was addressed in a study and found that confirmation of SARS-CoV-2 infection was delayed, on average, by 1.6 days from the onset of neurological manifestations, whereas in the case of encephalitis the delay was 3.9 days and 2.7 days for cerebrovascular events[32]. In the case of patient 3, diagnosed with encephalitis, the infection was confirmed only 7 days after the onset of symptoms.

Artigo Open Access sob uma licença CC BY-NC-ND (http://creativecommons.org/licenses/by-nc-nd/4.0/).

CONCLUSION

Our series presents some of the neurological manifestations that can occur as a result of SARS-CoV-2 infection, providing examples of cerebrovascular, PNS and CNS diseases. Although NeuroCOVID is not common as covid with respiratory syndrome, due to the pandemic situation and large number of patients infected, the number of severe neurological manifestations resulting from COVID-19 becomes significant. Moreover, this study demonstrates time of onset of neurological symptoms as the first manifestations of COVID-19, with no history of neurological problems or risk factors, should have SARS-CoV-2 infection included in the differential diagnosis, requiring biosecurity measures in order to prevent transmission and adopting specific treatments for the disease. Furthermore, patients fully recovered of COVID-19 should be followed up for a certain period of time after recovering, due to the risk of neurological complications, avoiding poor outcome.

More studies should be performed in order to identify NeuroCOVID precociously, improving treatment and prevention of severe forms of the disease.

CONFLICT OF INTEREST

The authors declare that there is no potential conflict of interest that could interfere with the impartiality of this scientific work.

REFERENCES

1. Gupta A, Madhavan MV, Sehgal K, Nair N, Mahajan S, Sehrawat TS et al. Extrapulmonary manifestations of COVID-19. Nat Med. 2020;26(7):1017–1032. DOI: https://dx.doi.org/10.1038/s41591-020-0968-3

2. WHO COVID-19 Dashboard [Internet]. Geneva: World Health Organization; c2020 [cited 2022 Feb 6]. Available from: https://covid19.who.int/

3. Rahman HS, Aziz MS, Hussein RH, Othman HH, Salih Omer SH, Khalid ES, et al. The transmission modes and sources of COVID-19: A systematic review. Int J Surg Open. 2020;26:125–36. DOI: https://dx.doi.org/10.1016/j.ijso.2020.08.017

4. Keyhanian K, Umeton RP, Mohit B, Davoudi V, Hajighasemi F, Ghasemi M. SARS-CoV-2 and nervous system: From pathogenesis to clinical manifestation. J Neuroimmunol. 2021;350. DOI: https://dx.doi.org/10.1016/j.jneuroim.2020.577436

5. Abboud H, Abboud FZ, Kharbouch H, Arkha Y, el Abbadi N, el Ouahabi A. COVID-19 and SARS-Cov-2 Infection: Pathophysiology and Clinical Effects on the Nervous System. World Neurosurg. 2020;140:49–53. DOI: https://dx.doi.org/10.1016/j.wneu.2020.05.193

6. Pascarella G, Strumia A, Piliego C, Bruno F, del Buono R, Costa F, et al. COVID-19 diagnosis and management: a comprehensive review. J Intern Med. 2020;288(2):192–206. DOI: https://dx.doi.org/10.1111/joim.13091

7. Ellul MA, Benjamin L, Singh B, Lant S, Michael BD, Easton A, et al. Neurological associations of COVID-19. Lancet Neurol. 2020;19:767–83. DOI: https://dx.doi.org/10.1016/S1474-4422(20)30221-0

8. Frontera J, Mainali S, Fink EL, Robertson CL, Schober M, Ziai W, et al. Global Consortium Study of Neurological Dysfunction in COVID-19 (GCS-NeuroCOVID): Study Design and Rationale. Neurocrit Care. 2020;33(1):25–34. DOI: https://dx.doi.org/10.1007/s12028-020-00995-3

9. Song E, Zhang C, Israelow B, Lu-Culligan A, Prado AV, Skriabine S, et al. Neuroinvasion of SARS-CoV-2 in human and mouse brain. J Exp Med. 2021;218(3). DOI: https://dx.doi.org/10.1084/jem.20202135

10. Chen X, Laurent S, Onur OA, Kleineberg NN, Fink GR, Schweitzer F, et al. A systematic review of neurological symptoms and complications of COVID-19. J Neurol. 2021;268:392–402. DOI: https://dx.doi.org/10.1007/s00415-020-10067-3

11. Meppiel E, Peiffer-Smadja N, Maury A, Delorme C, Landré S, Petitgars P, et al. Manifestations neurologiques associées à l'infection SARS-CoV-2: le registre français NeuroCOVID. Med Mal Infect. 2020;50(6):S20–1. DOI: https://dx.doi.org/10.1016/j.medmal.2020.06.047

12. Matschke J, Lütgehetmann M, Hagel C, Sperhake JP, Schröder AS, Edler C, et al. Neuropathology of patients with COVID-19 in Germany: a post-mortem case series. Lancet

Artigo Open Access sob uma licença CC BY-NC-ND (http://creativecommons.org/licenses/by-nc-nd/4.0/).

Neurol. 2020;19(11):919–29. DOI: https://dx.doi.org/10.1016/S1474-4422(20)30308-2

13. Varatharaj A, Thomas N, Ellul MA, Davies NWS, Pollak TA, Tenorio EL, et al. Neurological and neuropsychiatric complications of COVID-19 in 153 patients: a UK-wide surveillance study. Lancet Psychiatry. 2020;7(10):875–82. DOI: https://dx.doi.org/10.1016/S2215-0366(20)30287-X

14. Meppiel E, Peiffer-Smadja N, Maury A, Bekri I, Delorme C, Desestret V, et al. Neurologic manifestations associated with COVID-19: a multicentre registry. Clin Microbiol Infect. 2021;27(3):458–66. DOI: https://dx.doi.org/10.1016/j.cmi.2020.11.005

15. Maury A, Lyoubi A, Peiffer-Smadja N, de Broucker T, Meppiel E. Neurological manifestations associated with SARS-CoV-2 and other coronaviruses: A narrative review for clinicians. Rev Neurol. 2021;177:51–64. DOI: https://dx.doi.org/10.1016/j.neurol.2020.10.001

16. Hughes C, Nichols T, Pike M, Subbe C, Elghenzai S. Cerebral Venous Sinus Thrombosis as a Presentation of COVID-19. Eur J Intern Med. 2020;7(5). DOI: https://dx.doi.org/10.12890/2020_001691

17. Cavalcanti DD, Raz E, Shapiro M, Dehkharghani S, Yaghi S, Lillemoe K, et al. Cerebral Venous Thrombosis Associated with COVID-19. AJNR Am J Neuroradiol. 2020;41(8):1370–6. DOI: https://dx.doi.org/10.3174/ajnr.A6644

18. Medicherla CB, Pauley RA, de Havenon A, Yaghi S, Ishida K, Torres JL. Cerebral Venous Sinus Thrombosis in the COVID-19 Pandemic. J Neuroophthalmol. 2020;40(4):457–62. DOI: https://dx.doi.org/10.1097/WNO.0000000000001122

19. Kow CS, Zaihan AF, Hasan SS. Anticoagulant approach in COVID-19 patients with cerebral venous thrombosis. J Stroke Cerebrovasc Dis. 2020;29(12). DOI: https://dx.doi.org/10.1016/j.jstrokecerebrovasdis.2020.105222

20. Tu TM, Goh C, Tan YK, Leow AS, Pang YZ, Chien J, et al. Cerebral Venous Thrombosis in Patients with COVID-19 Infection: a Case Series and Systematic Review. J Stroke Cerebrovasc Dis. 2020;29(12). DOI: https://dx.doi.org/10.1016/j.jstrokecerebrovasdis.2020.105379

21. Valiuddin H, Skwirsk B, Paz-Arabo P. Acute transverse myelitis associated with SARS-CoV-2: A Case-Report. Brain Behav Immun. 2020;5. DOI: https://dx.doi.org/10.1016/j.bbih.2020.100091

22. Zubair AS, McAlpine LS, Gardin T, Farhadian S, Kuruvilla DE, Spudich S. Neuropathogenesis and Neurologic Manifestations of the Coronaviruses in the Age of Coronavirus Disease 2019. JAMA Neurol. 2020;77(8). DOI: https://dx.doi.org/10.1001/jamaneurol.2020.2065

23. Gittermann LMT, Feris SNV, Giacoman AvO. Relación entre COVID-19 y síndrome de Guillain-Barré en adultos. Revisión sistemática. Neurologia. 2020;35(9):646–54. DOI: https://dx.doi.org/10.1016/j.nrl.2020.07.004

24. Munhoz RP, Pedroso JL, Nascimento FA, Almeida SM de, Barsottini OGP, Cardoso FEC, et al. Neurological complications in patients with SARS-CoV-2 infection: a systematic review. Arq Neuropsiquiatr. 2020;78(5):290–300. DOI: https://dx.doi.org/10.1590/0004-282x20200051

25. Arnaud S, Budowski C, Ng Wing Tin S, Degos B. Post SARS-CoV-2 Guillain-Barré syndrome. Clin Neurophysiol. 2020;131(7):1652–4. DOI: https://dx.doi.org/10.1016/j.clinph.2020.05.003

26. Oliveira VFL de, Ferreira E de NM. Complicações Neurológicas oriundas da infecção por SARS-CoV-2: uma revisão da literatura. Rev Neurociênc. 2020;28:1–14. DOI: https://dx.doi.org/10.34024/rnc.2020.v28.10789

27. Abildúa MJA, Atienza S, Monteiro GC, Aguirre MEE, Aguayo LI, Álvarez EF, et al. Encefalopatías y encefalitis durante la infección aguda por SARS-CoV2. Registro de la Sociedad Española de Neurología SEN COVID-19. Neurologia. 2021;36(2):127–34. DOI: https://dx.doi.org/10.1016/j.nrl.2020.11.013

Artigo Open Access sob uma licença CC BY-NC-ND (http://creativecommons.org/licenses/by-nc-nd/4.0/).

28. Tandon M, Kataria S, Patel J, Mehta TR, Daimee M, Patel V, et al. A Comprehensive Systematic Review of CSF analysis that defines Neurological Manifestations of COVID-19. Int J Infect Dis. 2021;104:390–7. DOI: https://dx.doi.org/10.1016/j.ijid.2021.01.002

29. Espíndola OM, Brandão CO, Gomes YCP, Siqueira M, Soares CN, Lima MASD, et al. Cerebrospinal fluid findings in neurological diseases associated with COVID-19 and insights into mechanisms of disease development. Int J Infect Dis. 2021;102:155–62. DOI: https://dx.doi.org/10.1016/j.ijid.2020.10.044

30. Freire-Álvarez E, Guillén L, Lambert K, Baidez A, García-Quesada M, Andreo M, et al. COVID-19-associated encephalitis successfully treated with combination therapy. Clin Infect Pract. 2020;7–8. DOI: https://dx.doi.org/10.1016/j.clinpr.2020.100053

31. Hassan M, Syed F, Rajput HM, Mushtaq HF, Khan NU, Badshah M. SARS-CoV-2 infection with pneumonia and encephalitis. Brain Hemorrhages. 2021;2(3):134–6. DOI: https://dx.doi.org/10.1016/j.hest.2021.02.002

32. Cleret de Langavant L, Petit A, Nguyen QTR, Gendre T, Abdelhedi J, Djellaoui A, et al. Clinical description of the broad range of neurological presentations of COVID-19: A retrospective case series. Rev Neurol. 2021;177(3):275–82. DOI: https://dx.doi.org/10.1016/j.neurol.2021.01.004

Artigo Open Access sob uma licença CC BY-NC-ND (http://creativecommons.org/licenses/by-nc-nd/4.0/).